

The Interpositional Arthroplasty (OMS's membrane) for Rheumatoid Elbow; A Case Followed for 40 Years

Michio Minami¹ Yasuhiko Nishio¹ Makoto Kondo¹ Sadatoshi Kato¹
Hiroyuki Kato² Akio Minami³ Masamichi Usui⁴ Seiichi Ishii⁵

¹Hokkaido Orthopedic Memorial Hospital

² Department of Orthopaedic Surgery, Shinshu University School of Medicine

³Hokkaidoh Chuo Rosai Hospital Spinal Cord Injury Center

⁴ Orthopaedic Surgery of Hitsujigaoka Hospital

⁵ An Emeritus Professor of Sapporo Medical University

肘関節リウマチに対して中間挿入膜（OMS膜）を用いた関節形成術を行い40年経過した1例

三浪三千男¹ 西尾 泰彦¹ 近藤 真¹ 加藤 貞利¹
加藤 博之² 三浪 明男³ 薄井 正道⁴ 石井 清一⁵

¹北海道整形外科記念病院 ²信州大学整形外科

³北海道中央労災病院せき損センター

⁴札幌羊ヶ丘病院整形外科 ⁵札幌医科大学医学部名誉教授

OMS膜は馬の小腸の腸間膜をクロム化して、1950年代に北海道大学整形外科教室で開発された。開発にあたった三氏の頭文字をとってOMS膜と命名され、動物実験で組織への安全性を確認し、1970年代より臨床応用された。

現在68歳女性のリウマチ(RA)患者で、28歳時、左肘関節にOMS膜を用いた関節形成術を行い、その後、抗リウマチ剤による治療を続けた。左肘の経過は良く、RAの再発も毒性反応もなかった。RAの治療の効果は不十分であり、2010年より生物学的製剤投与を開始した。投与4年目頃より寛解期をむかえ改善してきた。同時に、左肘も順調な経過をとり、術後40年68歳時の可動域は $-40^{\circ} \sim 130^{\circ}$ と痛みもなく適合性に優れたX線学的関節再生が認められた。この症例では、OMS膜が長期にわたった骨、関節への親和性を継続し、適切な治療によるRAの低活動性の維持が良好な結果になったことを示唆していた。

Introduction

A 28-year-old woman with rheumatoid arthritis (RA) was surgically treated with interpositional arthroplasty (IPA) using the OMS's membrane (IPA-O) for the left elbow in 1976 and was followed for 40 years postoperatively. This is the first report of IPA for RA elbow followed for over 40 years.

A Case Report

This case was approved by the institutional review board of the hospital (ID: 53). The patient was a 28-year-old female with a two-year history of RA. The laboratory findings showed elevated erythrocyte sedimentation rate (ESR) at 75mm/1hr, C-Reactive Protein (CRP) being 4.7 mg/dl, and rheumatoid factor (RF) as being strongly positive. Consequently, she was diagnosed as active RA. The patient was treated with prednisolone (PSL) 5mg and metalcaptopril 150mg/a day and non-steroidal anti-inflammatory drugs (NSAIDs). The left elbow was most severely affected and showed remarkable swelling,

tenderness and local heat. The range of elbow motion was from -35° in extension to 105° in flexion accompanied by moderate pain. The X-ray of the left elbow at that time showed that it was in Stage III according to Steinbrocker's classification (Fig.1).

Surgical Procedures: ¹⁻²⁾

IPA-O was performed for this condition in 1976. Through a J-shaped Kocher's lateral skin incision, a dissection was made between the triceps muscle posteriorly and the brachioradialis and extensor carpi radialis longus muscles anteriorly to expose the lateral condyle of the humerus and the joint capsule over the lateral surface of the radial head. Distal to the radial head, the extensor carpi ulnaris was separated from the anconeus muscle, of which distal fibers were then longitudinally divided. The periosteum was reflected from the anterior and posterior surfaces of the distal humerus and the common origin of the extensor muscles from the lateral epicondyle, either by subperiosteal dissection or by detaching them from the bony insertion.

Key words : RA (関節リウマチ), elbow (肘関節), arthroplasty (関節形成術)

Address for reprints : Michio Minami, Hokkaido Orthopedic Memorial Hospital, 7-13-5-22 Hiragishi, Toyohira-Ku, Sapporo 062-0937 Japan

After incising the joint capsule longitudinally, the elbow joint was subsequently dislocated.

First, the proliferated synovium was totally removed and the radial head was resected. Then, the destroyed articular surface of the distal humerus was resected by 1.0 to 1.5 cm and the trochlear notch was formed so that it matched the shape of the end of the olecranon. The distal end of the humerus was then covered with one layer of the OMS's membrane (Fig.2A, 2B). After reducing the elbow joint, the periosteum and the triceps, the brachioradialis, the extensor carpi ulnaris and the anconeus muscles were tightly sutured. For closing procedures, the dissected muscles and ligaments were reattached to their anatomic positions and the elbow was immobilized with the posterior long arm splint. Three weeks after IPA-O, active motion and physical therapy were started.

Postoperative course

In 1988, the medications were changed to PSL 3.5 mg and Bucillamine 100mg/a day and methotrexate (MTX) 4mg/week until 2005. Since 2006, a smaller dose of PSL, conventional synthetic DMARDs (cs DMARDs) and MTX were given. Stomatitis and leucopenia developed in 2008, which were thought to be side effects caused by MTX. However, there was neither recurrence of synovitis nor toxic reactions from the OMS's membrane in the left elbow. The X-ray taken 27 years after IPA-O demonstrated that the articular surface was reformed and adapted according to its functional demands (Fig.3). The elbow maintained an active extension and flexion motion from -50° to 125° and was free from pain (Fig.4).

On the other hand, the control of RA was unsatisfactory. In 2010, biologic agents (b DMARDs) was administered to control RA activity. Treatment with cs and b DMARDs turned out to be very effective. The activity of RA was decreasing year by year. Table-1 demonstrates the events and treatments after cs and b DMARDs every two years from 2010 to 2016. These data clearly suggested that she achieved a remission of RA.

In April 2016 (in 40 years after IPA-O), the range of the elbow extension – flexion motion was from -40° to 130° with full forearm rotation and satisfactory function (Fig.5). She complained no pain and there was no swelling or tenderness on the left elbow. In addition, there had been neither recurrence of synovitis nor toxic reaction caused by the OMS's membrane. The plain radiographs showed that joint space was maintained with some remodeling of the articular surface (Fig. 6 AB), which was much better than that shown in the previous X-ray (Fig. 3).

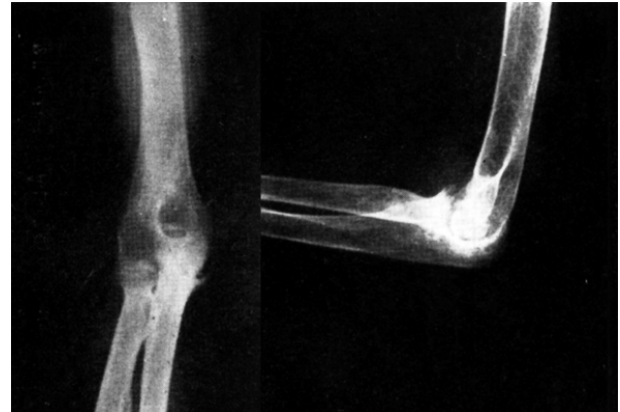

Fig.1 The X-ray of the left elbow

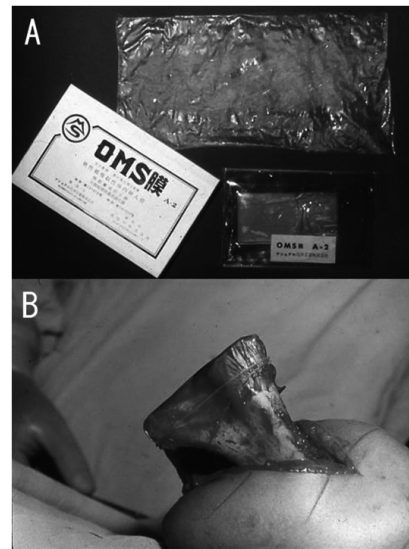


Fig.2 A: The OMS's membrane. B: The distal end of the humerus covered with one layer of the OMS's membrane

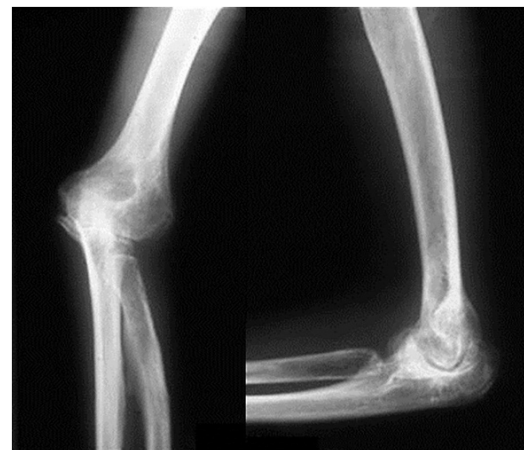

Fig.3 The X-rays of the left elbow 27 years after IPA-O

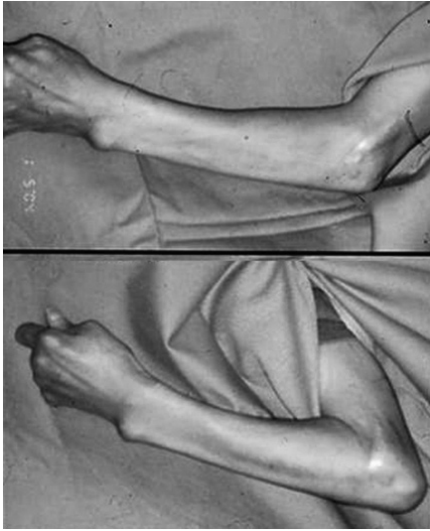


Fig.4 Extension and flexion of the left elbow
27 years after IPA-O

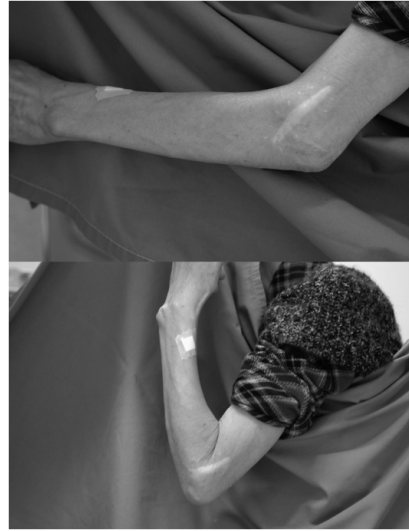


Fig.5 Extension and flexion of the left elbow
40 years after IPA-O

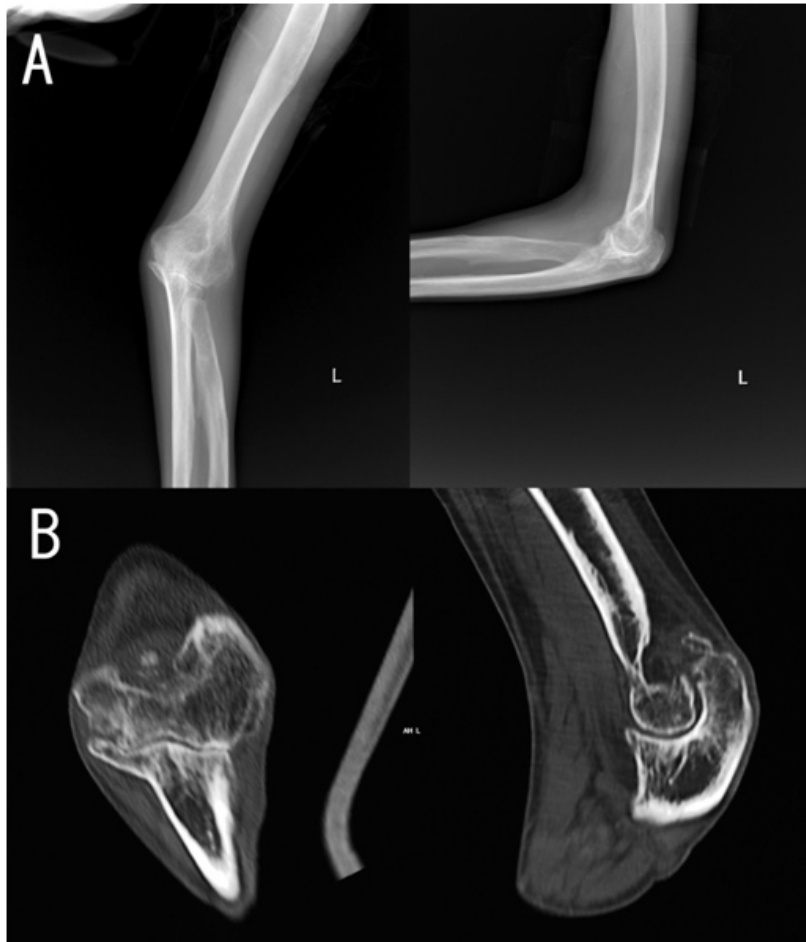

Fig.6 The X-rays and CT 40 years after IPA-O

Discussion

The IPA using an allogeneic membrane has been a challenging procedure to orthopedic surgeons. Burton is credited in 1827 with the first such operation for ankylosis of a joint³⁾. Early reports indicated that surgeons were making efforts to produce a pseudoarthrosis or neoarthrosis. However, the necessity of an interpositional membrane or materials was always recognized to prevent bone contact and recurrence of ankylosis³⁾.

The variety of resection arthroplasties with interpositional membranes or materials included the use of soft tissue by Murphy⁴⁾, the chromicized pig bladder by Bear in 1918⁶⁾, and fascia lata by Putti in 1920³⁾, owed shortly thereafter, in the USA by Campbell in 1921⁵⁾. Autogenous fascia lata then became the standard. In Europe, arthroplasty was popularized by Putti and Payr⁶⁾. Schüller⁷⁾ was the first to recommend the procedure for patients with RA. Autogenous or xeno graft has been used as an interpositional membrane in resection arthroplasties (cutis arthroplasty) of various joints⁸⁾. Since 1913, its successful use in the elbow has been reported by several authors^{9,10)}.

In Japan, the Jinnaka- Kono (JK membrane) was the most popular^{11,12)}. In 1950s, a new membrane was developed by chromizing the small intestinal serosa of the horse at Orthopedic Department of Hokkaido University¹³⁾. The membrane was named after three originator's initials: Dr. Y. Okuda, Dr. S. Matsuno (the late emeritus Prof. of Hokkaido Univ.) and Mr. J. Satsuma. They conducted several experiments to investigate the biological property of the OMS's membrane¹⁴⁻¹⁷⁾ and revealed that it had low biological toxicity, excellent affinity to the bone and joint and little character as a histologic foreign objects, although immunological search wasn't examined.

In our institute, IPA-O was performed for 12 elbows of 10 RA patients who were followed up for 12.2 years on an average. Recurrence of synovitis was observed in two elbows and instability in one, but no toxic reaction was observed. Four patients were free from pain^{1,2)}. The mechanism of the transformation to the new articulation in IPA-O was studied by Phemister and Miller¹⁸⁾ who demonstrated little histologic difference between the tissues in the resected area with and without interposition material.

For the current case, we considered that excellent remission of RA and new articulation of the elbow were very closely associated with the effective treatment with cs and b DMARDs, and the same medications would still be necessary to maintain her present condition of RA.

Since the 1980's, the total elbow arthroplasty has become common for the advanced rheumatoid elbow at our institute because production of the OMS's membrane was stopped in 1980.

Conclusions

We reported a 68-year-old female with RA treated with IPA-O for her left elbow and medications by cs and b DMARDs who has been successfully followed- up for 40 years. Medications achieved the remission of RA and her left elbow maintained excellent function and favorable remodeling of the articulation on X-ray. This case showed that the OMS's membrane had no toxicity and good affinity to the bone and joint over 40 years after surgery.

References

- 1) Minami M, Ishii S, Asai M, et al: Synovectomy and Arthroplasty for the Rheumatoid elbow. *Rinsho-seikei geka (Clinical orthopedics)*. 1974 ; 9 :73-8. (Japanese)
- 2) Matsuno S, Ishii S, Minami M: Arthroplasty of the elbow joint with the OMS's membrane. In: Kasiwagi D, ed. *Elbow joint*. Excerpta Medica, Amsterdam. 1985 ; 249-54.
- 3) Brown JE, McGaw WH, Shaw DT : Use of Cutis as an Interposing Membrane in Arthroplasty of the Knee. *J Bone Joint Surg Am*. 1958 ; 40 : 1003-18.
- 4) Murphy JB : Ankylosis: Arthroplasty: clinical and experimental. *JAMA*. 1905 ; 44 : 1573.
- 5) Bear WS : Arthroplasty with the Aid of Animal Membrane. *Am J Orthop Surg*. 1918 ; 16 : 1-29.
- 6) Phillip EW, Avarum IF, Morry BF: Interpositon Arthroplasty of the Elbow. In: Morrey BE, ed. *The Elbow and its Disorders*, Saunders, Philadelphia. 2001 ; 718-30.
- 7) Schüller M : Chirurgische Mitteilungen über die chronisch-rheumatischen Gelenkentzündungen. *Arch. kiln, Chir*. 1893 ; 45 : 153.
- 8) Oyemade GA : Fascial arthroplasty for elbow ankylosis. *Int Surg*. 1983 ; 68 : 81-4.
- 9) Froimson AI, Silva JE, Richey D : Cutis arthroplasty of the elbow joint. *J Bone Joint Surg Am*. 1976 ; 58 : 863-5.
- 10) Ljung P, Jonsson K, Larsson K, et al: Interposition arthroplasty of the elbow with rheumatoid arthritis. *J Shoulder and Elbow Surg*. 1996 ; 5 : 81-5.
- 11) Jinnaka S, Kono S : *Kansetu-keiseijutu (Arthroplasty) Nihon-Ishoshuppan*, Tokyo. 1949. (Japanese)
- 12) Kita M : Arthroplasty of the Elbow Using J-K Membrane. *Acta Orthop Scand*. 1977; 48: 450-5.
- 13) Matsuno S : Manufacture of the cut- get membrane and its function. *J J Orthop Ass*. 1950 ; 24 : 136-42.
- 14) Matsuno S : Experimental study of Arthroplasty with the cut- get membrane. *J Hokkaido Medicine (Sapporo)*. 1950 ; 25 : 85-90. (Japanese)
- 15) Matsuno S: Experimental study of arthroplasty with the OMS's membrane (A-1). *J J Orthop Ass*. 1950 ; 24 : 321-36. (Japanese)
- 16) Matsuno S, Matsuda Y, Oyoshi K : Experimental study of the irritability of the OMS's membrane. *Orthop Surg (Tokyo)*. 1952 ; 3 : 262-5. (Japanese)
- 17) Matsuno S, Oyoshi K : Experimental study of Arthroplasty with a single layer code of the porous OMS's membrane. *Orthop Surg (Tokyo)*. 1952 ; 3 : 262-5. (Japanese)
- 18) Phemister DB, Miller EM : The method of new joint formation in arthroplasty. *Gynecol Obstet*. 1924; 26 : 406.